

A Case Report on Tubercular Osteomyelitis of Mandible with Emphasis on Various Differential Diagnosis of Jaw Swellings

AMITA ARORA, SANGEETA LAMBA

ABSTRACT

Tuberculosis (TB) has been present in the human race for thousands of years. TB is a potentially fatal contagious disease that can affect almost any part of the body but lungs are the major site of damage. Extrapulmonary Tuberculosis (EPTB) is relatively

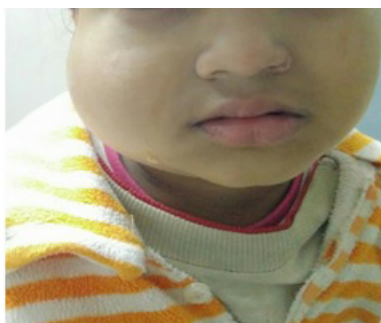neglected, however increasing in incidence. Extrapulmonary involvement can occur in isolation or along with a pulmonary focus as in the case of patients with disseminated TB. We are describing here a case of tubercular osteomyelitis involving the jaw in a 3 years old child which is a very rare site of bone TB.

Keywords: Contagious, Disseminated, Extrapulmonary

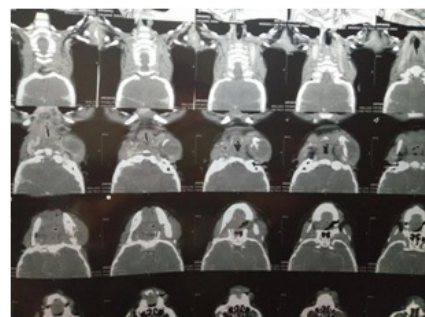
CASE REPORT

A 3-year-old male child presented to our Hospital with a large swelling on right cheek for 1.5 months which was gradually increasing in size [Table/Fig-1]. There was no history of pain, fever or cough in the child and there was negative family history of any chronic illness. There was negative history of any other disease/infection or hospitalization in the recent past. The child had received all the vaccinations till this age as per the immunization schedule including BCG vaccine. On extra oral examination, only facial asymmetry was present due to swelling on the right side which measured around 6x6cm in size. Swelling was firm in consistency, non-tender on palpation and non-fluctuant with normal overlying skin showing no signs of inflammation or any visible sinus/fistula. No pus discharge or bleeding was seen intra or extraorally. No dental caries was observed in any of the

tooth. No lymphadenopathy was found. Rest of the systemic examination was within normal limits. Thus, on the basis of history and examination, a clinical diagnosis of malignant soft tissue tumour was suspected with differentials included osteosarcoma, Ewing's sarcoma, rhabdomyosarcoma or lymphoma. Patient was sent for X-ray chest which revealed no active lesion in lungs. Routine hematological examination was then done which showed lymphocytosis and raised ESR. CT-scan of head and neck region showed a large destructive lesion involving the right side of mandible with a surrounding collection of pus/abscess formation [Table/Fig-2]. After taking proper consent from the child's father, USG guided FNA was performed from the mandibular swelling by an external approach using 22 gauge needle attached to 10 ml syringe which yielded around 12 ml of purulent material. Smears were prepared and stained with Geimsa stain which

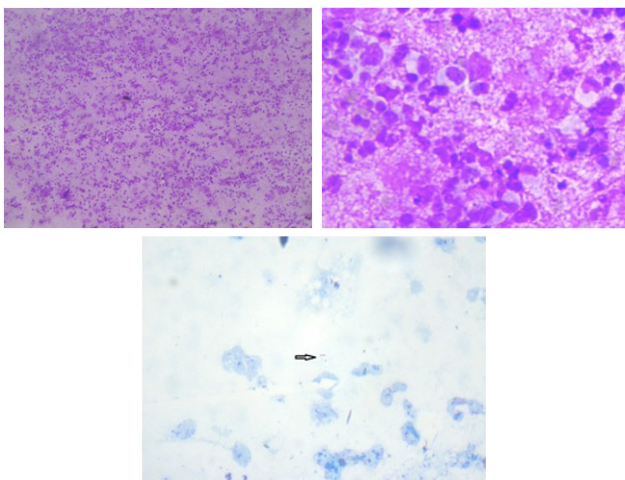


[Table/Fig-1]: Clinical picture showing right cheek swelling in a 3-year-old child.



[Table/Fig-2]: CT-scan image of the head and neck region showing destruction of right mandible with surrounding pus collection.

revealed mainly acute on chronic inflammatory cells lying in a background of necrosis. No atypical cells or granuloma were identified [Table/Fig-3,4]. So, a presumptive diagnosis of pyogenic abscess involving the mandible and overlying soft tissue was made, keeping in mind that infection might have caused by some oral pathogen gaining entry through the site of erupting tooth. As pus was aspirated, so further one of the kept smear was stained with Ziehl-Neelsen stain to look for acid fast bacilli and it came out to be positive [Table/Fig-5]. Simultaneously, some amount of aspirated pus was sent for culture and sensitivity which showed no growth (sterile culture), thus ruling out possibility of any other bacterial infection leading to osteomyelitis. Thus, a diagnosis of tubercular abscess with primary tubercular



[Table/Fig-3]: Geimsa stained cytomorphological picture of the lesion under 100X magnification. **[Table/Fig-4]:** Geimsa stained cytological smear showing inflammatory cells in a background of caseous necrosis under 400X magnification. **[Table/Fig-5]:** Ziehl-Neelsen stained FNA smear with an arrow pointing towards acid fast bacilli under oil power.

osteomyelitis of mandible was made. Following this, report was immediately conveyed to the treating pediatrician and he was started on thrice weekly DOTS regimen for a period of 6 months. Patient was called for follow-up after 2 months of intensive treatment during which his swelling had reduced slightly and routine blood tests, X-ray skull was done which revealed some changes of bone healing in the mandible. On completion of treatment, there was complete resolution of the swelling.

DISCUSSION

TB is becoming rampant in both developing and developed countries these days. As per the data provided by WHO in 2002, TB is a fatal disease which leads to almost 5000 deaths every day. However, WHO report in 2015 states there has been drop in mortality due to TB in subsequent years owing to improvement in effective diagnosis and treatment. While making comparisons in data provided from the year

2009 and 2014, the incidence of TB was 9.4 million and 9.6 million respectively, the increase in latter year was not due to increase in the spread of disease but due to improved national data. Whereas, if we look into the data on mortality from TB, it killed around 1.7 million people in 2009 which dropped to 1.5 million by 2014, thus showing an improvement taking place during these years.

EPTB especially of bones is an uncommon form of chronic infection which differs from pulmonary TB in its manifestations. Generally, EPTB is found in only 15-20% of all TB cases [1] while in HIV positive cases, chances of extrapulmonary and disseminated TB increases as immunosuppression advances (i.e. <300 CD4cells/ μ l) [2]. The incidence of bone TB among all cases of EPTB is around 10-20% [3] whereas, it accounts for only 1% of all TB cases in children [4]. It is seen that spine is the major site of predilection (constituting 50% cases of musculoskeletal TB).

TB of the flat bones of the skull is uncommon and that of the mandible is especially rare as it contains less cancellous bone [5,6]. Sixty percent of all cases of TB of jaw occur in children below the age of 16 years [7]. Mandible is a very rare primary site of involvement by TB as majority of the reported cases are secondary due to seeding from other sites in the body (mainly lungs) [8]. Therefore mandibular TB is rarely considered in the differential diagnosis of jaw swellings particularly if there is no pulmonary or any other organ involvement [7].

The infection may extend to the mandible by either hematogenous route (especially after trauma) or by infected sputum/infected raw cow milk through an open pulp in caries infected tooth or an extraction wound or mucosal abrasion or through gingival perforation in an erupting tooth or by extension to an underlying bone by a nearby soft tissue lesion.

In this case also it was clinically suspected as some pyogenic lesion which was proved as tubercular osteomyelitis on FNAC and ZN staining. On taking history later, it was found that the patient had been taking cow's milk since the age of 1 year so pathogen would have gone in from the site of mucosal opening of an erupting tooth.

Differential diagnosis of jaw swelling includes a wide range of entities such as anatomical variations, developmental anomalies, inflammatory (acute or chronic e.g. cellulitis/sialadenitis/parotid abscess/dental infections) and reactive diseases (peripheral giant cell granulomas/ fibromas/reactive lymphoid hyperplasia), cysts, and neoplasms (benign tumours of salivary gland/connective tissue origin and malignant epithelial/soft tissue tumours) [9].

TB of the jaw in children causes bone necrosis and sequestra formation; destructive changes may not be visible by conventional radiography until weeks after onset of infection. Hyperplastic changes usually predominate with formation of cold abscess which may burst either intra or extra orally forming single or multiple sinuses. Pathological fracture of

mandible may also occur [7].

The best way to diagnose TB is by culturing *Mycobacterium tuberculosis* organisms from samples obtained from various sites. However, this method is not very sensitive in diagnosing EPTB involving some poorly accessible sites due to low yield of the sample and low bacillary load. Techniques that are employed to obtain sample from extrapulmonary sites includes endoscopy, laparoscopy, ultrasound, Computed Tomography (CT), MRI through which aspirate or biopsy can be taken and subjected to microscopy, culture, cytology, histology. Therefore, USG/CT guided aspirate/biopsy is the recommended investigation in case of tubercular osteomyelitis.

New techniques based on molecular methods have been developed to aid the diagnosis of paucibacillary TB such as gene amplification methods (PCR as well as isothermal) developed for diagnosis of TB are demonstrably highly sensitive specially in culture negative specimens from different paucibacillary forms of disease. With these molecular methods, drug resistant mutants for drugs like rifampicin can be detected [10].

CONCLUSION

Due to the increasing incidence of TB in our country, clinical suspicion of Koch's osteomyelitis should be considered in all osteolytic jaw lesions especially in children. FNAC is a reliable cost-effective method which can be carried out in cases of jaw swelling. Direct AFB staining should be done routinely

and if positive, is completely diagnostic and negates the use of more expensive molecular techniques. Early diagnosis and treatment is essential to halt and possibly reverse the bony changes.

REFERENCES

- [1] Fanning A. Tuberculosis: 6. Extrapulmonary disease. CMAJ. 1999;160(11):1597-603.
- [2] L Annie. Tuberculosis and HIV. HIV In Site Knowledge Base. 2013. <http://hivinsite.ucsf.edu/InSite?page=kb-05-01-06>
- [3] Teo HE, Peh WC. Skeletal tuberculosis in children. *Pediatr radiol*. 2004;34:853.
- [4] Sequeira W, Co H, Block JA. Osteoarticular tuberculosis: Current diagnosis and treatment. *Am J Ther*. 2000;7:393-98.
- [5] Karjodkar F, Saxena VS, Maideo A, Sontakke S. Osteomyelitis affecting mandible in tuberculosis patients. *Journal of Clinical and Experimental Dentistry*. 2012;4(1):72-76.
- [6] Upadhyay S, Sharma A, Tuljapurkar V. Primary tuberculous osteomyelitis of the mandible mimicking a parotid fistula. *Braz. j. otorhinolaryngol*. 2011;77:3.
- [7] Gupta KB, Manchanda M, Yadav SPS, Mittal A. Tubercular osteomyelitis of mandible. *Indian journal of tuberculosis* 2005;52:147-50.
- [8] Imamura M, Kakihara T, Yamamoto K, Imai C, Tanaka A, Uchiyama M. Primary tuberculous osteomyelitis of the mandible. *Pediatr Int*. 2004;46:736-37.
- [9] Flaitz CM, Coleman GC. Differential diagnosis of oral enlargements in children. In: *Principles of Oral Diagnosis*: Mosby-Year Book. 1993. Pages-352-88.
- [10] Katoch VM. Newer diagnostic techniques for tuberculosis. *Indian J Med Res*. 2004;120(4):418-28.

AUTHOR(S):

1. Dr. Amita Arora
2. Dr. Sangeeta Lamba

PARTICULARS OF CONTRIBUTORS:

1. Senior Resident, Department of Pathology, ESI Hospital, Rohini, Delhi, India.
2. Head, Department of Pathology, ESI Hospital, Rohini, Delhi, India.

NAME, ADDRESS, E-MAIL ID OF THE CORRESPONDING AUTHOR:

Dr. Sangeeta Lamba,
Head, Department of Pathology,
ESI Hospital, Sec-15, Rohini, Delhi, India.
E-mail: sangeeta.lamba@gmail.com

FINANCIAL OR OTHER COMPETING INTERESTS:

None.

Date of Publishing: Jul 20, 2017